33 Other Vesiculobullous Diseases

José M. Mascaró Jr

Chapter Contents

Bullosis Diabeticorum 560
Coma Blisters 561
Friction Blisters 562
Bullous Cutaneous Small Vessel Vasculitis 563
Bullous Drug Eruptions 563
Bullous Insect Bite Reactions 563
Delayed Postburn/Postgraft Blisters 565
Edema Blisters 565
Additional Vesiculobullous Disorders 566

Vesiculobullous diseases of the skin encompass a wide range of entities, including autoimmune bullous diseases and inherited blistering disorders (see Chs. 28–32). This chapter focuses on the remaining non-infectious disorders in which cutaneous bullae develop and represent the primary clinical manifestation.

BULLOSIS DIABETICORUM

Synonyms: ▪ Diabetic bullae ▪ Bullous eruption of diabetes mellitus ▪ Bullous diabeticorum

Key features

- A rare condition associated with diabetes mellitus
- Tense blisters develop on normal-appearing skin in acral sites (feet, lower legs, hands); there is often an association with peripheral neuropathy
- Histologically, intraepidermal and/or subepidermal blisters are observed
- Spontaneous healing usually occurs in 2 to 6 weeks

History

Bullosis diabeticorum was first described by Kramer in 1930. In 1967, Cantwell & Martz[1] introduced the term "bullosis diabeticorum".

Epidemiology

The exact prevalence of bullosis diabeticorum is unknown. In a retrospective study of diabetic patients, the annual incidence was 0.16%[2]. The age of onset ranges from 15 to 85 years, with a mean age of 55 years. A 2:1 male-to-female ratio has been reported, and it occurs more frequently in the setting of longstanding diabetes and neuropathy.

Pathogenesis

Although bullosis diabeticorum has been related to trauma and the microangiopathy of diabetes, little is known about its cause. Diabetic patients can develop blisters after minimal trauma, and some authors have found a reduced threshold for inducing suction blisters in these patients[3,4]. There is no evidence of an infectious etiology.

Clinical Features

Bullosis diabeticorum is characterized by a sudden and spontaneous appearance of vesicles and bullae within normal-appearing, non-inflamed skin of the distal extremities of diabetics. The most frequent locations (in decreasing order) are the feet, distal legs, hands, and forearms. Bullae are rarely seen on the trunk. The lesions are usually asymptomatic, but occasionally there is a mild burning sensation. Blisters often develop "overnight" and in the absence of known trauma. The vesicles and bullae are tense and vary in diameter from 0.5 to several centimeters (Fig. 33.1). They contain a clear, sterile fluid that can be more viscous than that found in friction blisters.

Most patients have longstanding diabetes, but occasionally bullosis diabeticorum is a presenting sign of diabetes. It is associated with both insulin-dependent and non-insulin-dependent diabetes mellitus. Many patients have an associated polyneuropathy, retinopathy, or nephropathy.

Pathology

The histopathologic findings are heterogeneous. Initial reports described intraepidermal blisters, whereas more recent publications have usually described subepidermal bullae. It seems likely that the level of cleavage is subepidermal, and that intraepidermal blisters represent older lesions undergoing re-epithelialization. Direct immunofluorescence (DIF) examination is usually negative, although a few reports have described IgG or IgM and C3 deposits within dermal blood vessel walls. By electron microscopy, subepidermal blisters with a separation at the level of the lamina lucida or below the lamina densa have been described[5].

Differential Diagnosis

In porphyria cutanea tarda (PCT) and pseudoporphyria associated with dialysis and medications, the blisters are usually <1 cm in diameter and favor the hands rather than the feet and ankles. Complications of diabetes include both chronic renal failure and atherosclerotic cardiovascular disease and, as a result, patients may be receiving dialysis

Fig. 33.1 Bullosis diabeticorum. A large, tense bulla overlying the medial malleolus. Note the absence of erythema or edema in the surrounding skin.

Downloaded for Anonymous User (n/a) at Egyptian Knowledge Bank from ClinicalKey.com by Elsevier on March 10, 2024. For personal use only. No other uses without permission. Copyright ©2024. Elsevier Inc. All rights reserved.

and/or diuretics. The distal extremity is also a common site for fixed drug eruptions, but bullae develop on an inflammatory base. Localized bullous pemphigoid and epidermolysis bullosa acquisita (EBA) are differentiated by histologic examination and DIF, as well as by an accentuation of lesions at sites of friction in patients with EBA. If there is surrounding erythema, warmth, and tenderness, the possibility of bullous cellulitis must be considered.

Treatment

Most patients have spontaneous healing of their lesions within 2 to 6 weeks. To relieve pressure or improve appearance, the blisters can be cleansed with alcohol and then a small window is placed in the most dependent portion of the blister roof. The sites should be washed daily to prevent secondary infection followed by application of petrolatum. Occasionally, a secondary soft-tissue infection does develop, requiring systemic antibiotics or surgical intervention[2].

COMA BLISTERS

Synonyms: ■ Coma bullae ■ Drug-induced coma blisters ■ Barbiturate blisters ■ Neurologic blisters

Key features

- Associated with loss of consciousness, neurologic diseases, or prolonged immobilization
- Tense blisters develop on normal-appearing skin
- Histologically, intraepidermal or subepidermal blisters are observed, with a characteristic necrosis of sweat glands
- Spontaneous healing occurs within 1 to 2 weeks

Introduction

In some comatose patients, blisters, primarily within sites of pressure, will develop within 48–72 hours of loss of consciousness. Although historically associated with barbiturate overdose, they can be seen in the setting of coma due to other causes including medications (e.g. opioids), infections (e.g. viral encephalitis), metabolic disturbances (e.g. hypoglycemia), and neurologic dysfunction (e.g. cerebrovascular accidents).

History

Coma blisters were first described in 1806 by Dominique Larrey, Napoleon's surgeon, who noticed these lesions in soldiers who had been comatose from carbon monoxide intoxication.

Epidemiology

In 1952, Holten reported the appearance of coma blisters in 4% of a series of 501 patients with barbiturate poisonings[6]. In another study, blisters were found in 6.5% of barbiturate overdoses[7]. Although a number of reported cases have been associated with barbiturate overdose, blisters have also been observed in those whose comas were induced by overdosage of other medications, including opioids, benzodiazepines, hypnotics, tricyclic antidepressants and antipsychotics, as well as alcohol intoxication[8]. Similar lesions have also been described in patients with non-drug-induced coma due to carbon monoxide poisoning, head trauma, cerebrovascular accidents, viral encephalitis, hypoglycemia, diabetic ketoacidosis, or hepatic encephalopathy[9,10]. In addition, bullous lesions have been observed following surgical procedures requiring general anesthesia[11] and in non-comatose patients, in particular those with severe neurologic disease or prolonged immobilization (e.g. secondary to accidents)[12].

Pathogenesis

The pathogenesis is unclear. A direct toxic drug effect has been implicated, particularly because of the association with drug intoxication and the frequent finding of eccrine gland necrosis (many drugs are thought to be excreted by sweat glands). However, this would not explain the non-drug-induced cases. Therefore, pressure, friction, and local hypoxia have been implicated as etiologic factors. The pressure/ischemic hypothesis is currently favored and is supported by the observation that most (if not all) lesions appear at sites of pressure.

Clinical Features

Lesions develop at body sites exposed to maximum pressure during unconsciousness or immobilization. They first appear 24 hours after the onset of coma as blanchable erythematous patches or plaques that progress to violaceous plaques. Blisters or erosions then develop within 48–72 hours after the onset of coma at these sites (Fig. 33.2). If the patient survives, the erosions usually heal spontaneously over 1 to 2 weeks. In some individuals, residual scarring can result. Compression neuropathies and non-traumatic rhabdomyolysis are additional complications that may be seen in patients with coma bullae[8–10,12,13]. As mentioned previously, the same type of blisters can occur in patients with prolonged immobilization or neurologic diseases (Fig. 33.3).

Fig. 33.2 Coma bullae. Blisters developed in an area of pressure in a previously comatose patient.

Fig. 33.3 Neurologic blisters. Tense blisters on the dorsal aspect of the fingers on the hemiplegic side in a patient with a history of a cerebrovascular accident.

Downloaded for Anonymous User (n/a) at Egyptian Knowledge Bank from ClinicalKey.com by Elsevier on March 10, 2024. For personal use only. No other uses without permission. Copyright ©2024. Elsevier Inc. All rights reserved.

Pathology

The blisters are predominantly subepidermal. However, intraepidermal blisters are also observed as the result of re-epithelialization of older lesions or epidermal spongiosis. There is a variable degree of epidermal necrosis. Sweat gland necrosis is a characteristic finding (Fig. 33.4), and focal necrosis of the epithelium of the pilosebaceous units can also be seen. There is only a sparse inflammatory cell infiltrate. DIF is usually negative, but deposits of IgG, IgM, and/or C3 have been found within the walls of dermal blood vessels[8,9].

Differential Diagnosis

In most patients, the clinical setting alone is sufficient to make the diagnosis (Fig. 33.5). A cutaneous biopsy will allow differentiation from friction blisters. An intraepidermal blister cavity just below the granular layer is seen in friction blisters, whereas a subepidermal split with sweat gland/follicular necrosis is characteristic of coma bullae. Based upon the distribution pattern, clinical appearance, and histologic findings, multiple fixed drug eruption can be excluded.

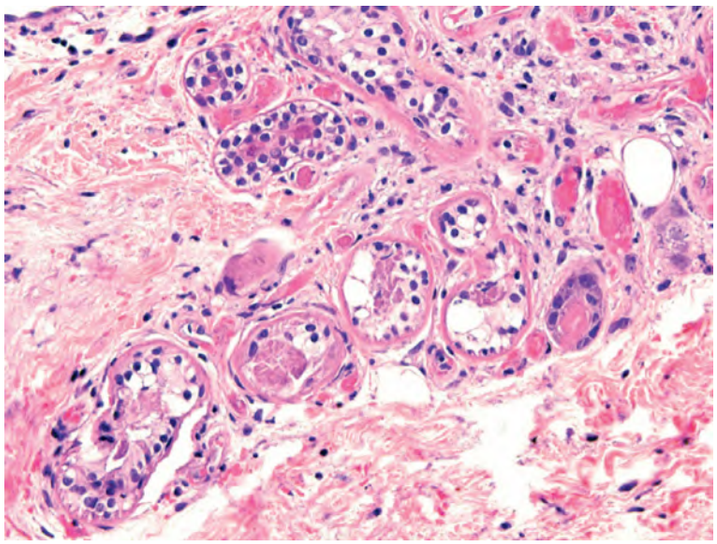

Fig. 33.4 Bulla due to prolonged immobilization ("coma blister") – histopathologic features. Following a fall and hip fracture, the patient remained immobilized on the floor for two days. Detection of the characteristic sweat gland necrosis aided in the diagnosis.

Treatment

Coma blisters heal spontaneously over 1 to 2 weeks. In non-comatose patients, frequent postural changes help to resolve and prevent the disorder.

FRICTION BLISTERS

Key features

- Friction blisters occur most commonly on the soles and heels
- They are the result of repeated friction, e.g. walking or running in ill-fitting shoes; they may also develop on the palms and fingers if a repetitive action is performed
- Histologically, blistering occurs just below the stratum granulosum

Epidemiology

Friction blisters are very common in the general population. Almost every person remembers developing such lesions when wearing a new pair of shoes. They are particularly common in young and active individuals, especially those engaged in the military and sports. In a military study at a Combat Support Hospital, the prevalence of foot friction blisters was 33% and they were more common in those who were unable to break in their boots[14].

Pathogenesis

Frictional shearing forces occur within the epidermis when the surface of an object rubs against the skin surface. Repetition of this rubbing action over a period of time can induce the appearance of blisters. Rubbing of moist skin produces higher frictional forces than with very dry or very wet skin[15]. Poorly fitting shoes, heat, and sweating are predisposing factors.

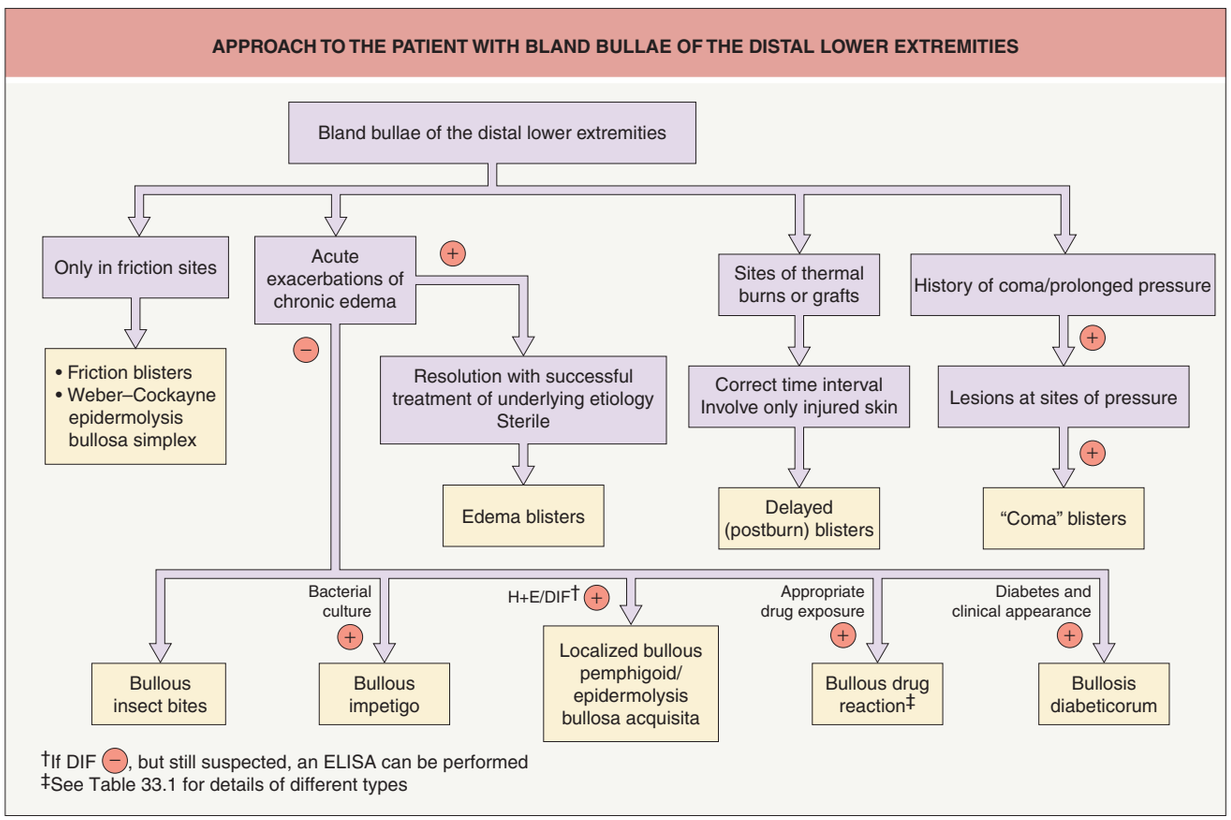

Fig. 33.5 Approach to the patient with bland bullae of the distal lower extremities.

Downloaded for Anonymous User (n/a) at Egyptian Knowledge Bank from ClinicalKey.com by Elsevier on March 10, 2024. For personal use only. No other uses without permission. Copyright ©2024. Elsevier Inc. All rights reserved.

Clinical Features

Friction blisters most frequently develop in areas with thick stratum corneum (soles, heels, palms, fingers). They are particularly common in sites where friction is intense and repeated (e.g. feet). The lesions initially begin as erythematous macules at sites of friction and later develop into blisters. The patients complain of an associated burning sensation or pain, and the blister fluid may be clear or blood-tinged.

Pathology

Friction blisters are intraepidermal blisters resulting from necrosis of keratinocytes. The level of the split is variable but usually in the stratum spinosum just below the stratum granulosum. The roof of the blister is formed by the stratum corneum, the stratum granulosum, and some cellular debris. Pale and degenerated keratinocytes that stain faintly are found within the upper portion of the floor of the blister cavity. The deeper layers of the epidermis are normal[16]. There is only a sparse perivascular inflammatory infiltrate in the superficial dermis.

Differential Diagnosis

In most patients, friction blisters can be easily diagnosed clinically. The localized variant of epidermolysis bullosa simplex (formerly Weber–Cockayne) is suspected when there is an exaggerated response to friction; histologic examination of a fresh or induced blister should show separation subepidermally or within the basal layer of the epidermis. EBA can also mimic friction blisters, but it is differentiated by histologic examination, DIF, and ELISA (see Fig. 33.5).

Treatment

Friction blisters can heal spontaneously without treatment. Drainage of blister contents via a small "window" in the blister roof relieves pressure and discomfort and prevents the accumulation of fluid; it also allows the blister roof to remain largely intact. Hydrocolloid or other dressings can also be utilized.

BULLOUS CUTANEOUS SMALL VESSEL VASCULITIS

Occasionally, patients with cutaneous small vessel vasculitis will develop superimposed vesicles and bullae, especially on the distal extremities (Fig. 33.6). These blisters are often hemorrhagic and can progress to ulceration. Edema of the lower extremities may also be present. In children, vesicles have been observed more frequently in IgA vasculitis (Henoch–Schönlein purpura) than in non-IgA vasculitis[17]. Histologically, a leukocytoclastic vasculitis is seen (in addition to a subepidermal blister with epidermal necrosis), which differentiates this entity from other blistering diseases. This may be a sign of more severe disease (see Ch. 24).

Fig. 33.6 Bullous variant of cutaneous small vessel vasculitis. *Courtesy Jeffrey P. Callen, MD.*

BULLOUS DRUG ERUPTIONS

Key features

- Some drug eruptions can present as blistering eruptions
- These eruptions can be localized or widespread
- Clinical, histologic, and immunofluorescence findings vary, depending on the type of drug eruption

Vesicles and bullae can develop in a variety of drug eruptions, which are outlined in Table 33.1 and discussed in detail in other chapters.

BULLOUS INSECT BITE REACTIONS

Synonyms (for exaggerated insect bite reactions in the setting of hematologic malignancies): ▪ Eosinophilic dermatosis of hematologic malignancy ▪ Eosinophilic dermatosis associated with hematological disorders

Key features

- Bullous insect bite reactions are fairly common, particularly in children, although patients often do not recall being bitten
- Severe insect bite reactions as well as insect bite-like reactions can occur in patients with hematologic malignancies, in particular chronic lymphocytic leukemia

Introduction

Although most insect bite reactions present as pruritic erythematous papules (see Ch. 85), vesiculobullous reactions are not uncommon.

History

An exaggerated reaction to insect bites in patients with chronic lymphocytic leukemia (CLL) was first described in 1965 by Robert Weed, and it has been increasingly recognized over the past two decades.

Epidemiology

There seems to be no difference in the incidence of insect bites based on sex, race, or age. Certain individuals may be bitten more frequently because of their body temperature, odor, use of perfumes, or carbon dioxide excretion. Children tend to have more severe reactions than adults because the latter tend to become desensitized by repeated exposures over time.

Patients with CLL, as well as other hematologic malignancies (e.g. non-Hodgkin lymphomas, acute leukemias, multiple myeloma), can develop both exaggerated reactions to insect bites and insect bite-like reactions[18,19]. The latter term is used to describe lesions that resemble insect bites clinically and histologically, but for which a clear link to insect bites cannot be established[20]. These exaggerated reactions can precede the diagnosis of the hematologic malignancy; in a large retrospective study of patients with CLL, the eruption preceded the diagnosis in 20% of patients[21]. Of note, no relationship to disease activity has been observed. More recently, these reactions have been referred to as "eosinophilic dermatosis associated with hematological disorders" or "eosinophilic dermatosis of hematologic malignancy"[22]; the term "eosinophilic dermatosis of myeloproliferative disease" is inaccurate, as CLL is not a myeloproliferative disorder (see Ch. 121).

Downloaded for Anonymous User (n/a) at Egyptian Knowledge Bank from ClinicalKey.com by Elsevier on March 10, 2024. For personal use only. No other uses without permission. Copyright ©2024. Elsevier Inc. All rights reserved.

BULLOUS DRUG ERUPTIONS		
Disease	**Characteristic features**	**Commonly implicated drugs**
Fixed drug eruption (see Ch. 21)	• Sharply circumscribed erythematous to dusky violaceous patches • Central blisters or erosions may appear • Often resolves with postinflammatory hyperpigmentation • Recurrence at same location(s) following drug re-exposure	Sulfonamides, NSAIDs, tetracyclines, barbiturates, aspirin, acetaminophen (paracetamol), metronidazole, phenolphthalein
Stevens–Johnson syndrome (SJS), toxic epidermal necrolysis (TEN) (see Ch. 20)	• Prodrome of fever and painful skin • Areas of dusky erythema associated with epidermal detachment (varying from <10% [SJS] to >30% [TEN]) • Mucosal involvement	NSAIDs, antibiotics (sulfonamides and β-lactams), aromatic anticonvulsants, lamotrigine, allopurinol, immune checkpoint inhibitors
Drug-induced autoimmune blistering diseases (see Chs. 29–31)	• Primarily, linear IgA bullous dermatosis, bullous pemphigoid, pemphigus • Diagnosis based on histopathologic findings, immunofluorescence studies, and drug history	• Linear IgA bullous dermatosis: vancomycin > β-lactams, captopril, NSAIDs • Bullous pemphigoid: diuretics (especially furosemide), antibiotics, immune checkpoint inhibitors, gliptins • Pemphigus: captopril, β-lactams, penicillamine, gold
Drug-induced pseudoporphyria (see Ch. 49)	• Eruption resembles porphyria cutanea tarda • Porphyrins are within normal limits	NSAIDs (especially naproxen), nalidixic acid, thiazides, furosemide, tetracyclines, voriconazole
Acute generalized exanthematous pustulosis (see Ch. 21)	• Acute onset, usually occurring within 2 days of drug exposure • Areas of erythema studded with pustules; occasionally vesicles • Fever, malaise, leukocytosis	β-lactams, macrolides, pristinamycin, terbinafine, calcium channel blockers (diltiazem), hydroxychloroquine, carbamazepine, acetaminophen, metronidazole, immune checkpoint inhibitors
Phototoxic drug eruptions (see Ch. 87)	• Limited to sun-exposed areas • Resembles exaggerated sunburn	Tetracyclines (especially doxycycline), quinolones, psoralens, NSAIDs, diuretics, voriconazole, pirfenidone, BRAF inhibitors, EGFR inhibitors
Bromoderma and iododerma (see Ch. 21)	• Acneiform lesions, papulopustules, nodules, or even vegetating lesions simulating pemphigus vegetans • Clear or hemorrhagic blisters can develop (more common in iododerma)	Bromides, iodine-containing drugs (e.g. amiodarone), radiographic contrast media
Palmoplantar erythrodysesthesia (acral variant of toxic erythema of chemotherapy [TEC]; see Ch. 21)	• Painful erythema develops primarily on the palms, soles, and digits following chemotherapy administration • The skin becomes edematous, its color changes to dark red or violet, and blisters and erosions may develop • With severe TEC, bullae can be generalized	Cytarabine, doxorubicin, capecitabine, 5-fluorouracil (especially prolonged infusions), busulfan, multikinase inhibitors (e.g. sorafenib, sunitinib), taxanes, clofarabine, pralatrexate

Table 33.1 Bullous drug eruptions. Occasionally, eczematous drug reactions (e.g. secondary to warfarin, calcium channel blockers, angiotensin converting enzyme [ACE] inhibitors, angiotensin II receptor blockers) and systemic contact dermatitis can be papulovesicular; patients with drug reaction with eosinophilia and systemic symptoms (DRESS)/drug-induced hypersensitivity syndrome (DIHS) and drug-induced Sweet syndrome can also develop vesicles. Coma blisters and bullous small vessel vasculitis are discussed in the text. EGFR, epidermal growth factor receptor; NSAIDs, nonsteroidal anti-inflammatory drugs.

Pathogenesis

Most lesions are the result of an individual's immune response to insect antigens introduced by the bite. Both humoral (IgE-mediated) and cell-mediated immunity (delayed hypersensitivity) are involved. Initial bites typically do not produce significant lesions, but sensitization occurs over a few weeks. Subsequent bites then induce a stronger reaction and even bullae formation. With time, repeated bites can result in desensitization. In the case of bullous bed bug reactions, cutaneous vasculitis may be playing a role[23].

In patients with NK/T cell lymphomas, severe hypersensitivity to mosquito bites has been well documented and a possible role for the EBV-induced clonal proliferation of NK cells has been raised[24]. For patients with ALK-positive anaplastic large cell lymphoma, the possibility has been raised that insect bite-associated antigens lead to an influx of T lymphocytes, some of which bear t(2;5). The release of cytokines then results in activation of these cells, expression of NPM-ALK (nucleophosmin–anaplastic lymphoma kinase) fusion protein, and subsequent uncontrolled proliferation[25]. In patients with B cell malignancies, an increased production of IL-4 and IL-5 may explain associated tissue eosinophilia[20].

Fig. 33.7 Bullous insect bite reactions. The serous blister fluid is sterile and the ankle is a common site. *Courtesy Luis Requena, MD.*

Clinical Features

Insect bites usually appear as intensely pruritic erythematous papules or nodules. They are usually grouped, and a linear arrangement is commonly seen. However, vesicular and bullous bite reactions are not uncommon, and blisters can develop centrally within papules or as bland vesiculobullae (Fig. 33.7). Flea bites are the most likely to cause blisters, especially on the legs, and bedbug bites can also be bullous. Some insects (e.g. fire ants) can produce pustular lesions. In patients with hematologic malignancies, the exaggerated reactions consist of persistent papulonodules, vesicles, bullae, and even necrotic lesions (Fig. 33.8).

Downloaded for Anonymous User (n/a) at Egyptian Knowledge Bank from ClinicalKey.com by Elsevier on March 10, 2024. For personal use only. No other uses without permission. Copyright ©2024. Elsevier Inc. All rights reserved.

Fig. 33.8 Exaggerated insect bite-like reactions in a patient with B cell chronic lymphocytic leukemia. Both bullae and erosions at sites of ruptured bullae are present. *Reprinted with permission from Cerroni L. Skin Lymphomas: The Illustrated Guide, 5ed. Oxford: Wiley-Blackwell, 2020.*

Pathology

The typical pattern is that of a superficial and deep perivascular and periadnexal lymphocytic infiltrate with abundant eosinophils. A wedge-shaped pattern is characteristic. During the initial phase, intraepidermal spongiotic vesicles may be present and they can be associated with eosinophilic spongiosis. Pronounced dermal edema leads to the formation of subepidermal blisters. Sometimes, epidermal necrosis develops. Flame figures (extruded eosinophilic granules aggregated onto collagen fibers that are classically associated with eosinophilic cellulitis) can be observed, particularly in the exaggerated reactions seen in patients with hematologic malignancies.

Differential Diagnosis

The presence of intense pruritus and lesion distribution usually suggests a bullous bite reaction. However, these reactions can mimic bullous pemphigoid, linear IgA bullous dermatosis, bullous erythema multiforme, bullous impetigo, allergic contact dermatitis, or even viral infections.

Treatment

Most patients with bullous insect bites can be managed with drainage of blisters plus topical corticosteroids and systemic antihistamines to relieve pruritus. In the most severe reactions, a short course of systemic corticosteroids may be necessary. Systemic corticosteroids can lead to improvement of eosinophilic dermatosis of hematologic malignancy, but lesions tend to recur when the dose is reduced. Dupilumab may represent a therapeutic option in these patients[26]. Protective clothing and insect repellants are important preventative measures (see Ch. 85).

DELAYED POSTBURN/POSTGRAFT BLISTERS

Key features

- Delayed postburn and postgraft blisters represent an under-reported condition
- Tense blisters develop weeks to months after the initial injury has healed
- Blistering can persist for several weeks or months

Introduction

Delayed blisters have been observed weeks to months after the initial healing of second-degree thermal burns, donor sites of split-thickness skin grafts, and recipient sites of split-thickness skin grafts[27,28].

History

The first report of this phenomenon is attributed to Barker and Cotterill in 1980.

Epidemiology

Delayed blisters have received little attention in the literature. However, it appears to occur to some degree in almost every patient with a thermal burn involving more than 30% of the body surface area[28]. Most descriptions refer to patients with thermal burns, where delayed blisters have been observed on the spontaneously healed skin, graft donor sites, and graft recipient sites[27]. They have also been seen after skin grafting for toxic epidermal necrolysis and within laser-resurfaced skin[29].

Pathogenesis

The exact pathogenesis is not known. The antigenic components of the normal dermal–epidermal junction appear sequentially during fetal life or wound healing. Therefore, it has been hypothesized that this phenomenon is due to the enhanced fragility of a newly synthesized, "immature" dermal–epidermal junction[27,28]. In fact, in conventional scars, a subepidermal cleft is not an unusual histopathologic finding.

Clinical Features

Tense vesicles or blisters develop several weeks after the injured skin (burned, donor site, recipient site) has completely healed. In one study, blisters appeared between 19 and 55 days after the patients had sustained their burns, with an average of 37 days[28]. Blisters do not develop within uninvolved skin. Although they heal spontaneously, there is a tendency for recurrences over a period of weeks to months.

Pathology

Histologically, subepidermal blisters with minimal inflammatory infiltrate are seen. Electron microscopy has shown that the blisters occur either in the dermis (below the dermal–epidermal junction) or intraepidermally through the basal keratinocytes. DIF studies have been negative. Immunofluorescence mapping has shown a diminished or variable expression of dermal–epidermal junction antigens, including type IV and type VII collagens, laminin, and bullous pemphigoid antigen[27].

Differential Diagnosis

Blistering associated with a healed injured site can also be due to herpetic infection, ischemia (in the case of graft recipient sites), or autoimmune bullous diseases. Herpetic infection can be excluded by a negative PCR, viral culture, Tzanck smear, direct fluorescent antibody test, and/or biopsy findings; ischemia is diagnosed on the basis of clinical findings; and autoimmune blistering diseases can be excluded by histologic features, DIF/IIF examination, and ELISA.

Treatment

These blisters heal spontaneously with simple care, topical antibiotics, wound dressings, and local compression.

EDEMA BLISTERS

Synonyms: ▪ Edema bullae ▪ Stasis blisters ▪ Hydrostatic bullae

Downloaded for Anonymous User (n/a) at Egyptian Knowledge Bank from ClinicalKey.com by Elsevier on March 10, 2024. For personal use only. No other uses without permission. Copyright ©2024. Elsevier Inc. All rights reserved.

Fig. 33.9 Edema bullae on the thigh of an infant. The bullae are tense and are surrounded by edematous skin. Desquamation from a ruptured bulla is also seen.

Key features

- Edema blisters develop in patients with an acute exacerbation of chronic edema, particularly of the lower extremities, and in the setting of anasarca
- The tense bullae are usually non-inflammatory, but are surrounded by edematous skin
- Blisters resolve when the edema resolves

Epidemiology

This phenomenon has received little attention in the literature. These blisters are not infrequent and usually develop in elderly and immobile hospitalized patients as well as in the setting of anasarca. In a study of 13 patients, the mean age was 74 years[30].

Pathogenesis

The bullae usually develop on the legs in association with an acute exacerbation of chronic edema. Edema develops when the capillary filtration rate exceeds lymphatic drainage. This can be due to hypoalbuminemia, congestive heart failure, renal disease, hepatic cirrhosis, venous occlusion (thrombosis) or drugs, particularly calcium channel blockers. Cutaneous vesicles and bullae also occur with acute exacerbations of lymphedema.

Clinical Features

Due to gravitational effects and venous hypertension, most patients develop blisters on the distal lower extremities, particularly the dorsum of the foot and ankle. With acute exacerbations of chronic edema, blisters appear and enlarge slowly to reach a diameter of up to several centimeters. The bullae are tense and asymptomatic, and the surrounding skin is edematous. The sterile blister fluid is usually clear, but it can be serous or hemorrhagic. In patients with anasarca, there is a more widespread distribution (Fig. 33.9).

Pathology

Marked epidermal spongiosis is observed, with dilated dermal blood vessels and a mild inflammatory infiltrate. The dermis is markedly edematous with wide separation of collagen bundles. In some cases, a subepidermal blister is observed. DIF is negative.

Differential Diagnosis

Blistering in the setting of acute edema is usually not difficult to diagnose. However, the possibility of bullous pemphigoid, bullosis diabeticorum, or bullous drug eruption must also be considered. The correct diagnosis can usually be established via the clinical history and physical examination (see Fig. 33.5). If needed, bullous pemphigoid can be excluded by negative DIF/IIF examinations and ELISA.

ADDITIONAL VESICULOBULLOUS DISORDERS	
Disorder	**Characteristic features**
Fracture blisters	• Tense bullae that develop within edematous skin and overlie bony fractures (Fig. 33.10) • Most common sites: distal tibia, ankle, foot, elbow, wrist • Thought to be due to shearing forces related to the injury plus post-traumatic edema
Sucking blisters	• Seen in newborns in areas accessible to the infant's mouth, e.g. forearm (see Fig. 34.8A) • Develop *in utero*
Bullous dermatitis artefacta (self-inflicted injury)[31,32]	• Can be produced by a thermal, electrical, or chemical burn as well as application of a vesicant, coolant, or "salt and ice" (see Ch. 88) • Histologic features vary depending upon etiology, but the most common pattern is a subepidermal blister with epidermal necrosis +/– dermal damage
Jellyfish stings	• Intense pain followed shortly by a burning sensation or pruritus as well as erythema and edema • Linear vesiculobullae and occasionally necrosis may also appear • Flagellate distribution corresponds to sites of contact with the jellyfish tentacles
PUVA-induced acrobullous dermatosis	• Sudden appearance of sterile, tense blisters, usually on the distal extremities • Due to weakening of epidermal–dermal cohesion plus friction or trauma • DDx: phototoxicity (more widespread) and PUVA-induced bullous pemphigoid

Table 33.2 Additional vesiculobullous disorders. Sites of frostbite can also develop vesicles. DDx, differential diagnosis.

Fig. 33.10 Fracture blisters. Multiple blisters, containing serous or hemorrhagic fluid, developed on the lower extremity following blunt trauma to the thigh. The resultant hematoma and fracture was accompanied by edema of the affected limb.

Treatment

These blisters resolve rapidly when the cause of the edema is successfully treated. Diuretics, discontinuation of calcium channel blockers, leg elevation, and compressive bandages (followed by maintenance compression hose) may prove helpful.

ADDITIONAL VESICULOBULLOUS DISORDERS

These are summarized in Table 33.2.

Additional figures available in our eBook (see inside front cover for access code).

Downloaded for Anonymous User (n/a) at Egyptian Knowledge Bank from ClinicalKey.com by Elsevier on March 10, 2024. For personal use only. No other uses without permission. Copyright ©2024. Elsevier Inc. All rights reserved.

eFig. 33.1 Bullosis diabeticorum. A tense blister on the palm as well as desquamation at sites of previous bullae.

eFig. 33.2 Friction blisters. Tense blisters that developed on the shin of the author after continuous rubbing against a ski boot.

eFig. 33.3 Friction blisters. Erythema and a vesicle developed on the index finger after prolonged rubbing against a knife handle.

eFig. 33.4 Bullous variant of cutaneous small vessel vasculitis. The patient had chronic lower extremity edema. *Courtesy Jean L. Bolognia, MD.*

eFig. 33.5 Bullous variant of cutaneous small vessel vasculitis. Multiple vesicles within a purpuric plaque in a child with IgA vasculitis (Henoch–Schönlein purpura).

eFig. 33.6 Ofloxacin-induced linear IgA bullous dermatosis. This represents one form of bullous drug eruption. Although the initial clinical diagnosis was Stevens–Johnson syndrome or toxic epidermal necrolysis, the annular configuration and peripheral location of the bullae plus the histologic and DIF findings led to the diagnosis of linear IgA bullous dermatosis.

Downloaded for Anonymous User (n/a) at Egyptian Knowledge Bank from ClinicalKey.com by Elsevier on March 10, 2024. For personal use only. No other uses without permission. Copyright ©2024. Elsevier Inc. All rights reserved.

eFig. 33.7 Bullous insect bite reactions. This presentation can sometimes be misdiagnosed as localized bullous pemphigoid. *Courtesy Julie V. Schaffer, MD*.

eFig. 33.8 Bullous insect bite reactions on the distal leg. Several tense bullae that may be misdiagnosed as localized bullous pemphigoid. *Courtesy Karynne O. Duncan, MD*.

eFig. 33.9 Bullous bedbug bite reactions. This patient presented with generalized papulovesicles, vesicles, and bullae and was initially misdiagnosed as bullous pemphigoid.

eFig. 33.10 Exaggerated insect bite-like reactions in a patient with chronic lymphocytic leukemia. There are multiple vesicles and hemorrhagic crusts on an inflammatory base.

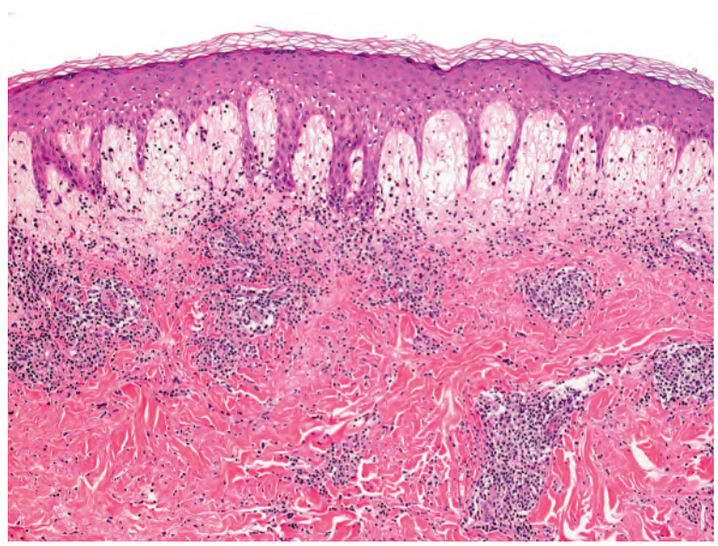

eFig. 33.11 Bullous bug bite reaction – histopathologic features. In addition to intense papillary dermal edema, there is a prominent perivascular mononuclear cell infiltrate in the upper and mid dermis. Note the basket-weave pattern of the stratum corneum, suggesting an acute process. *Courtesy Lorenzo Cerroni, MD*.

Downloaded for Anonymous User (n/a) at Egyptian Knowledge Bank from ClinicalKey.com by Elsevier on March 10, 2024. For personal use only. No other uses without permission. Copyright ©2024. Elsevier Inc. All rights reserved.

eFig. 33.12 Edema bulla in the setting of an acute exacerbation of lower extremity edema. Given the size of the bulla and its sterility, the initial differential diagnosis would include bullosis diabeticorum. *Courtesy Dennis L. Cooper, MD.*

eFig. 33.13 Fracture blisters. Sterile bland bullae develop in areas of edema following bone fractures. *Courtesy Ian Odell, MD, PhD.*

Downloaded for Anonymous User (n/a) at Egyptian Knowledge Bank from ClinicalKey.com by Elsevier on March 10, 2024. For personal use only. No other uses without permission. Copyright ©2024. Elsevier Inc. All rights reserved.